



1. LÉKAŘSKÁ FAKULTA  
UNIVERZITY KARLOVY V PRAZE



# Ultrazvuková diagnostika pooperačních infekčních komplikací

Michal Zikán

*Onkogynekologické centrum  
1. LF UK a VFN  
Praha*



Absces

~ 10%

Peritonitida

Infikovaný pahýlový hematom

Krvácení

Lymfatická kolekce

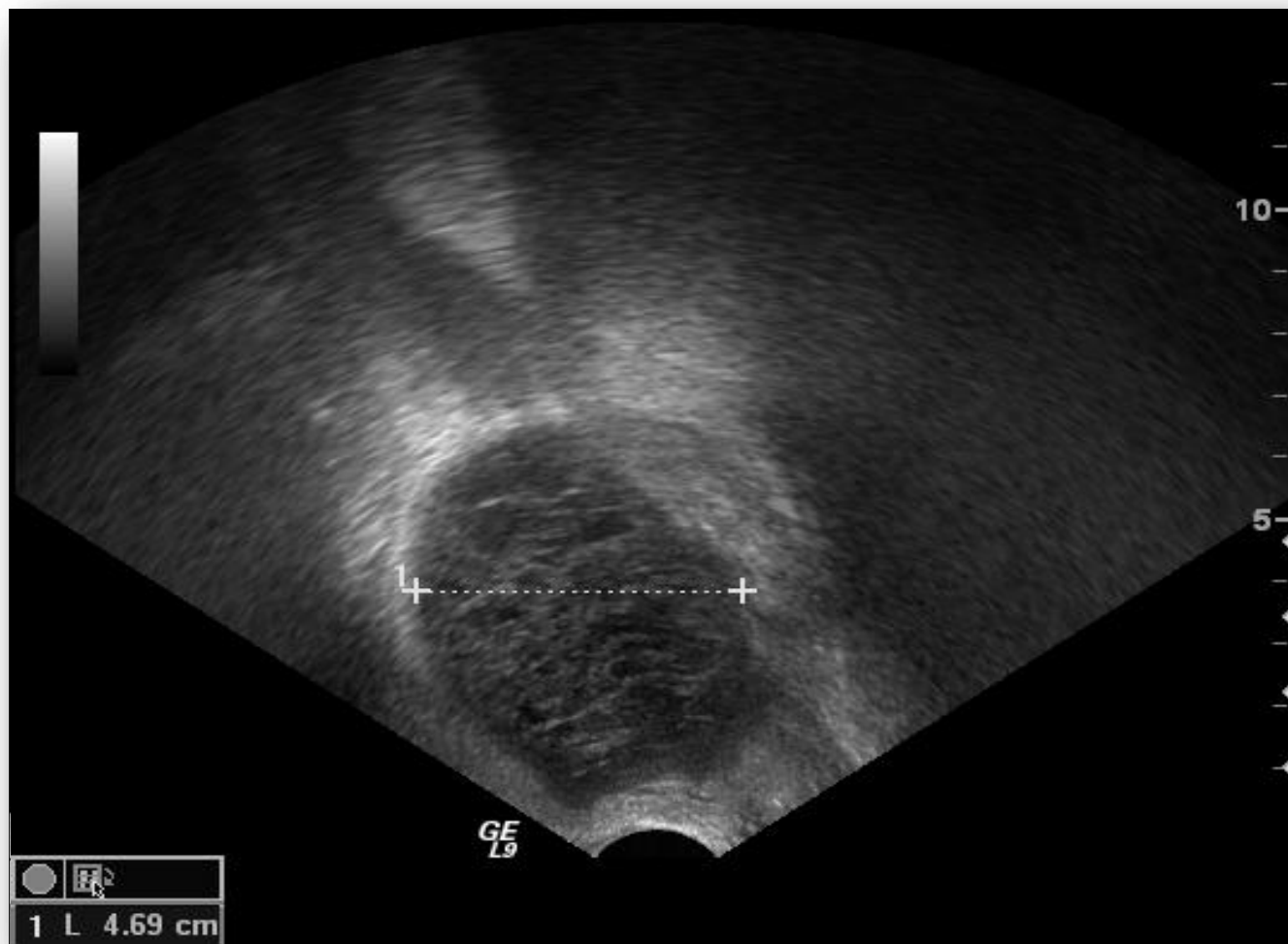Volná tekutina

Močovod



## Hysterektomie

Abdominální	10,5%
Vaginální	13,0%
Laparoskopická	9,0%



literární data: 2 – 58 %



## Lymfadenektomie 2006 - 2010

PLN	380	} 161 lymfocyst (20,13%)
PLN+PALN	331	
PALN	89	
<hr/>		
	800	

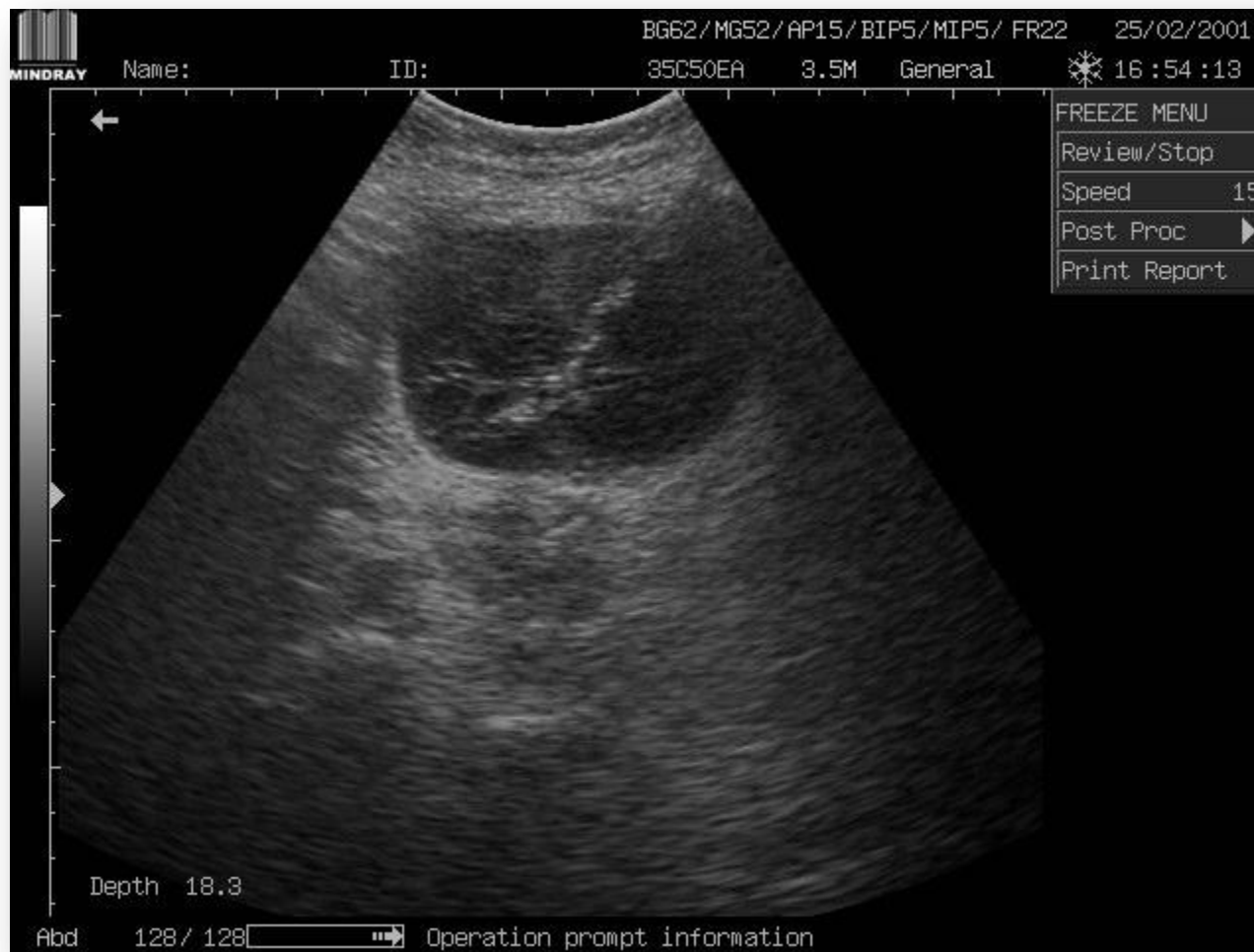

**45 symptomatických  
(5,63%; 27,9%)**



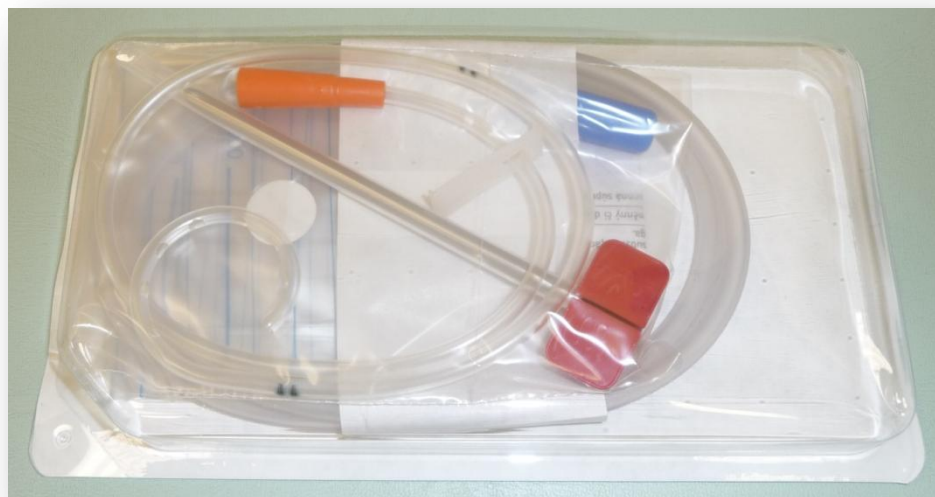Bolest ←  
Akutní lymfedém ←  
Dysurie ←  
Ostrukce močovodu ←  
Záněť ←







# 1. LÉKAŘSKÁ FAKULTA UNIVERZITY KARLOVY V PRAZE

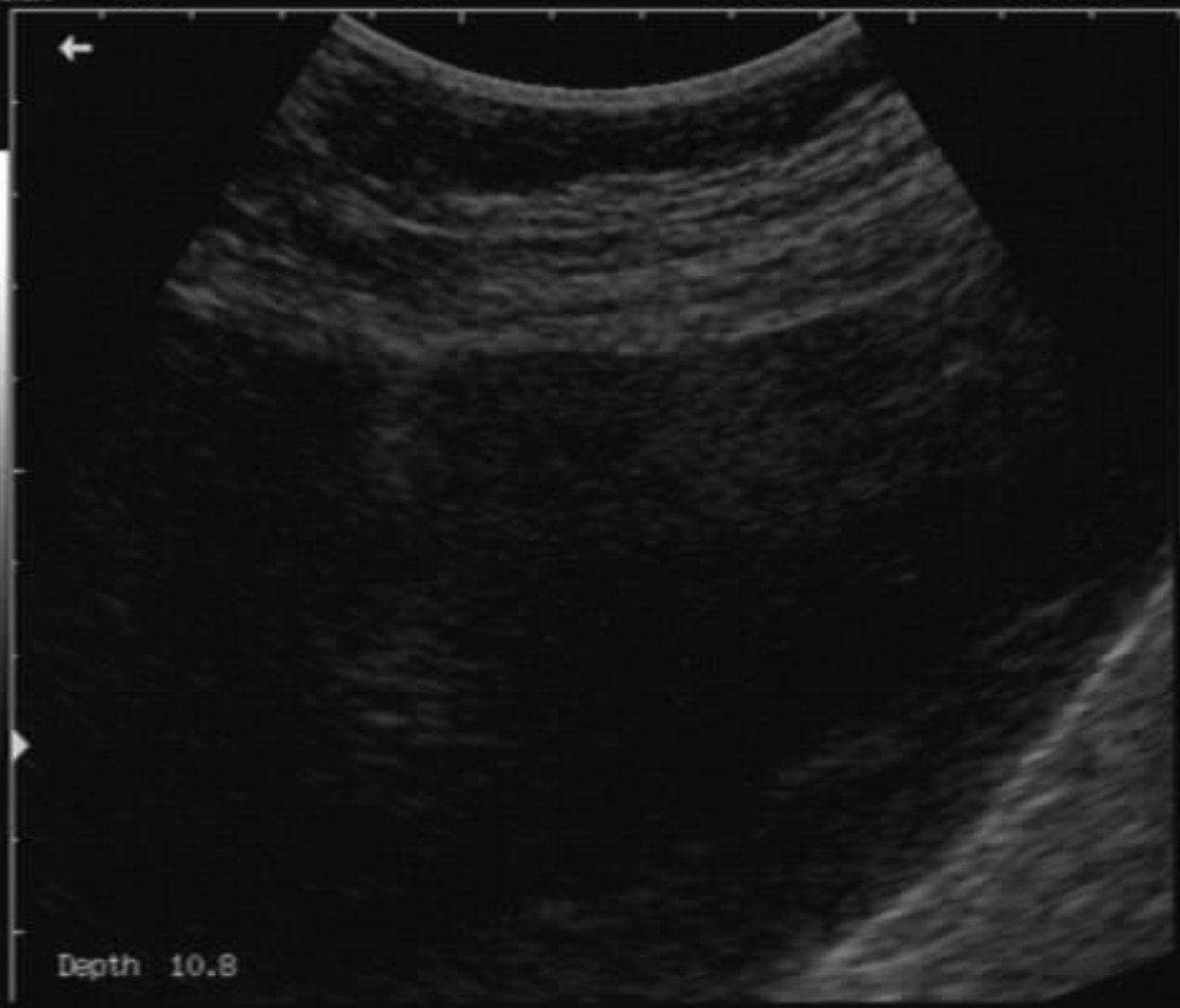





BG44/MG34/AP15/BIPS/MIP5/FR36 07/07/2001

Name: ID: 35C50EA 3.5M General 23:10:02

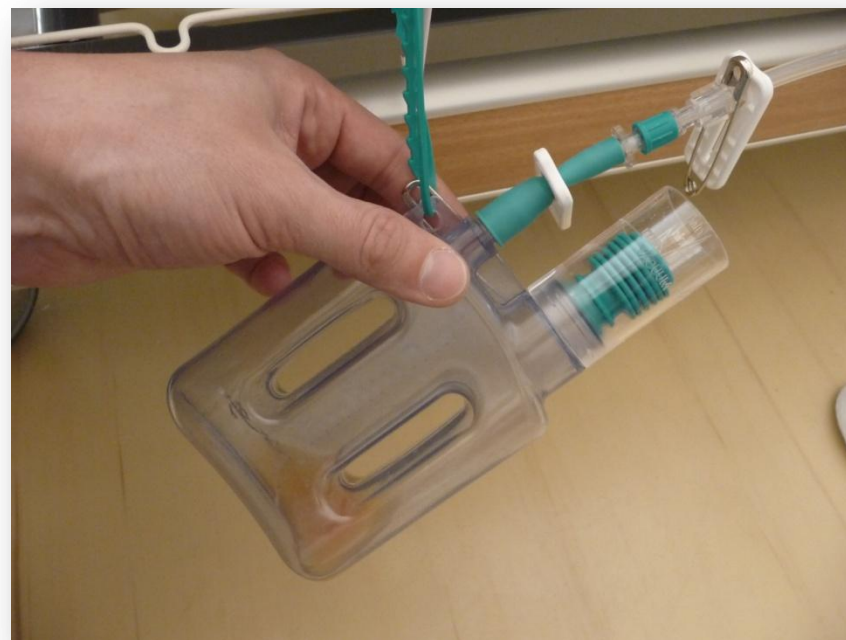
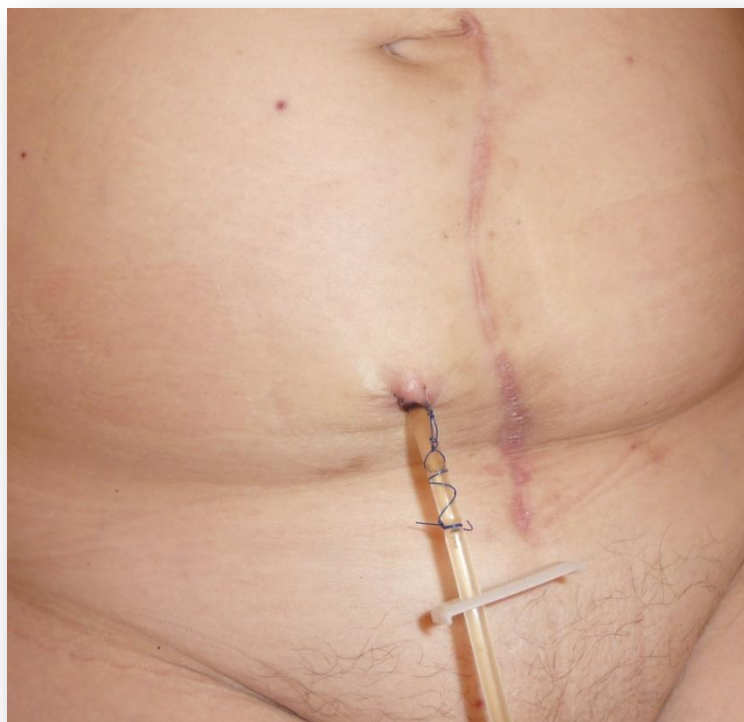
B MODE MENU	
Dyn Rng	58
Edge	1
Smooth	0
Frame Avg	4
Soften	1
B AGC	1
Noise Rst	0
Scan Mode	▶
Post Proc	▶
NeedleGuide	

Depth 10.8

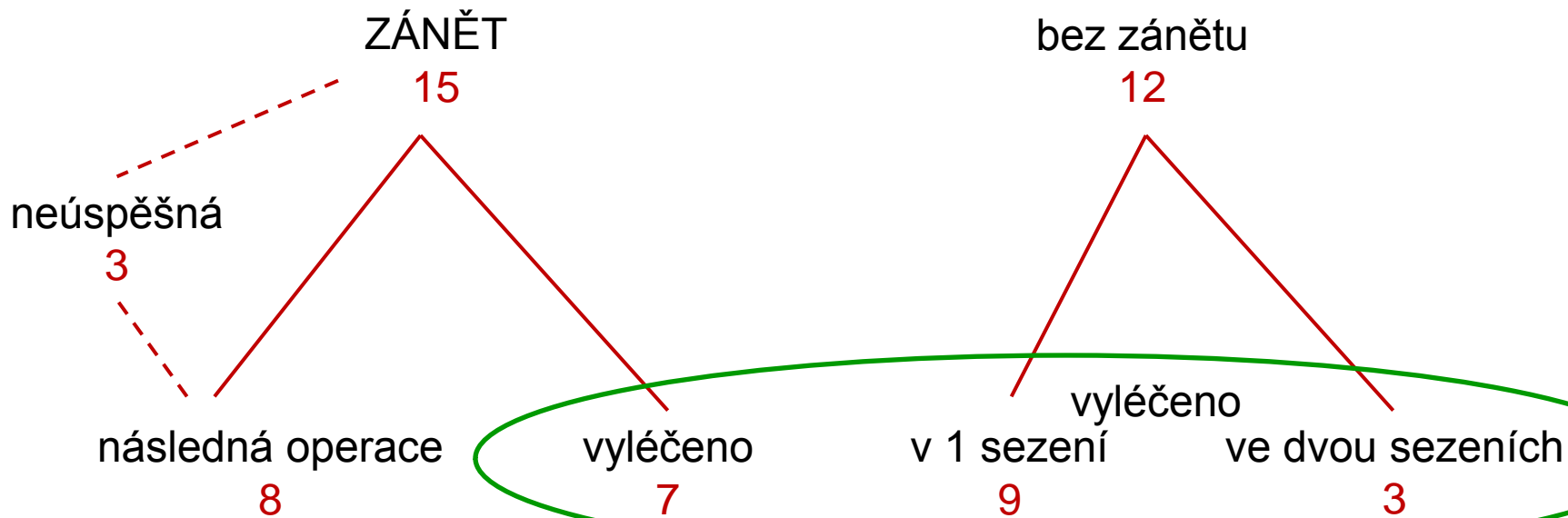
Abd

Operation prompt information

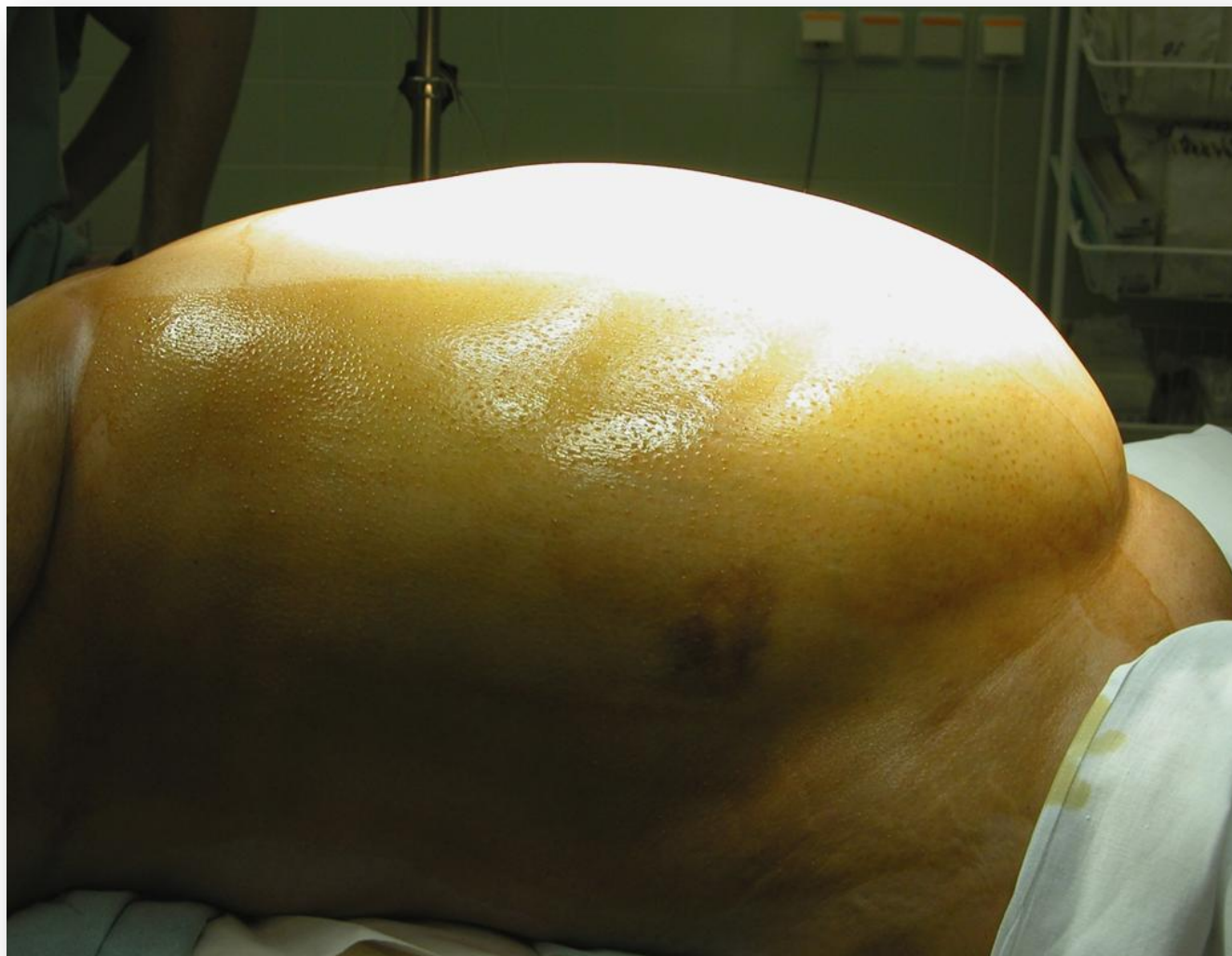


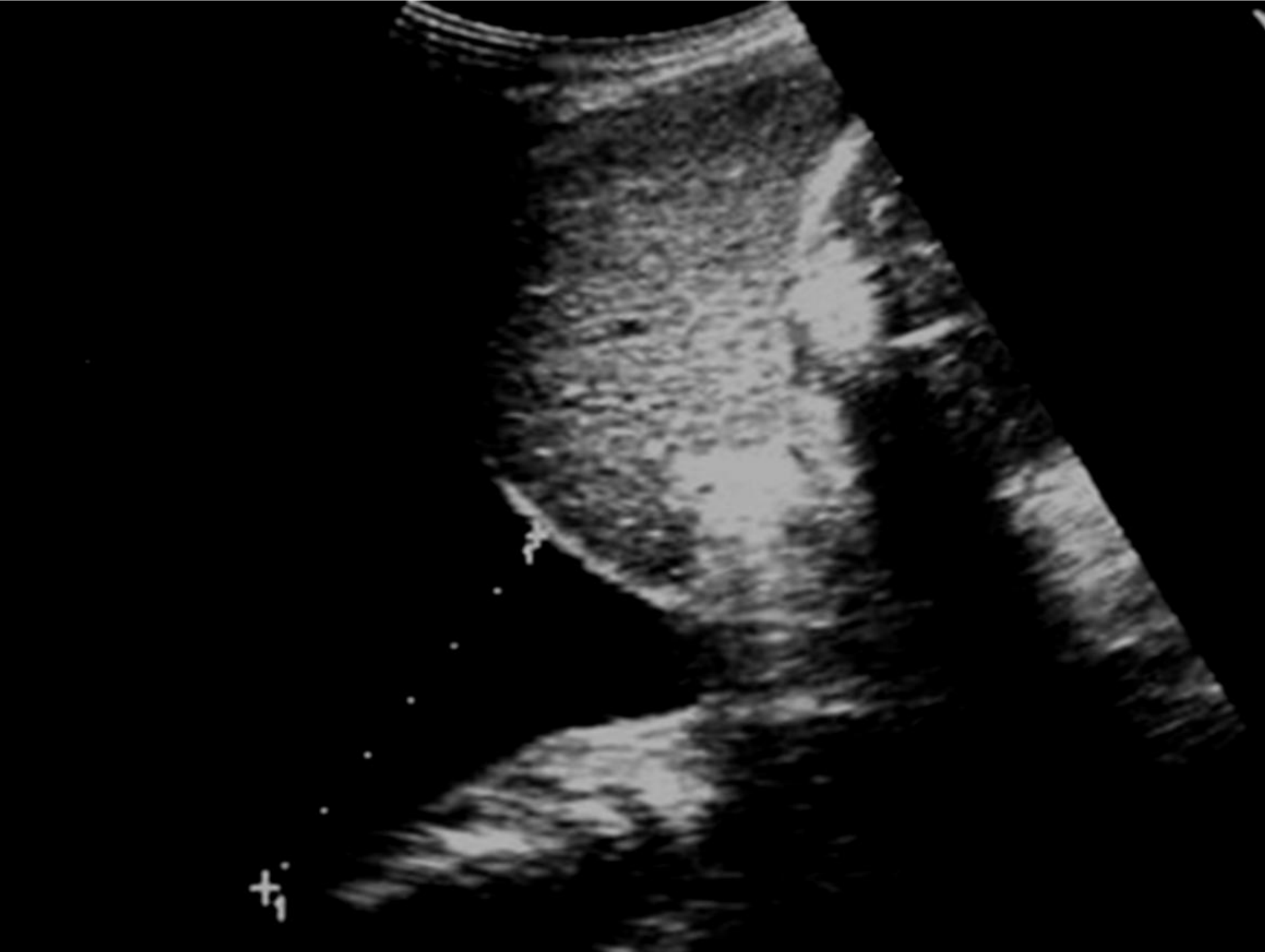
27 intervencí

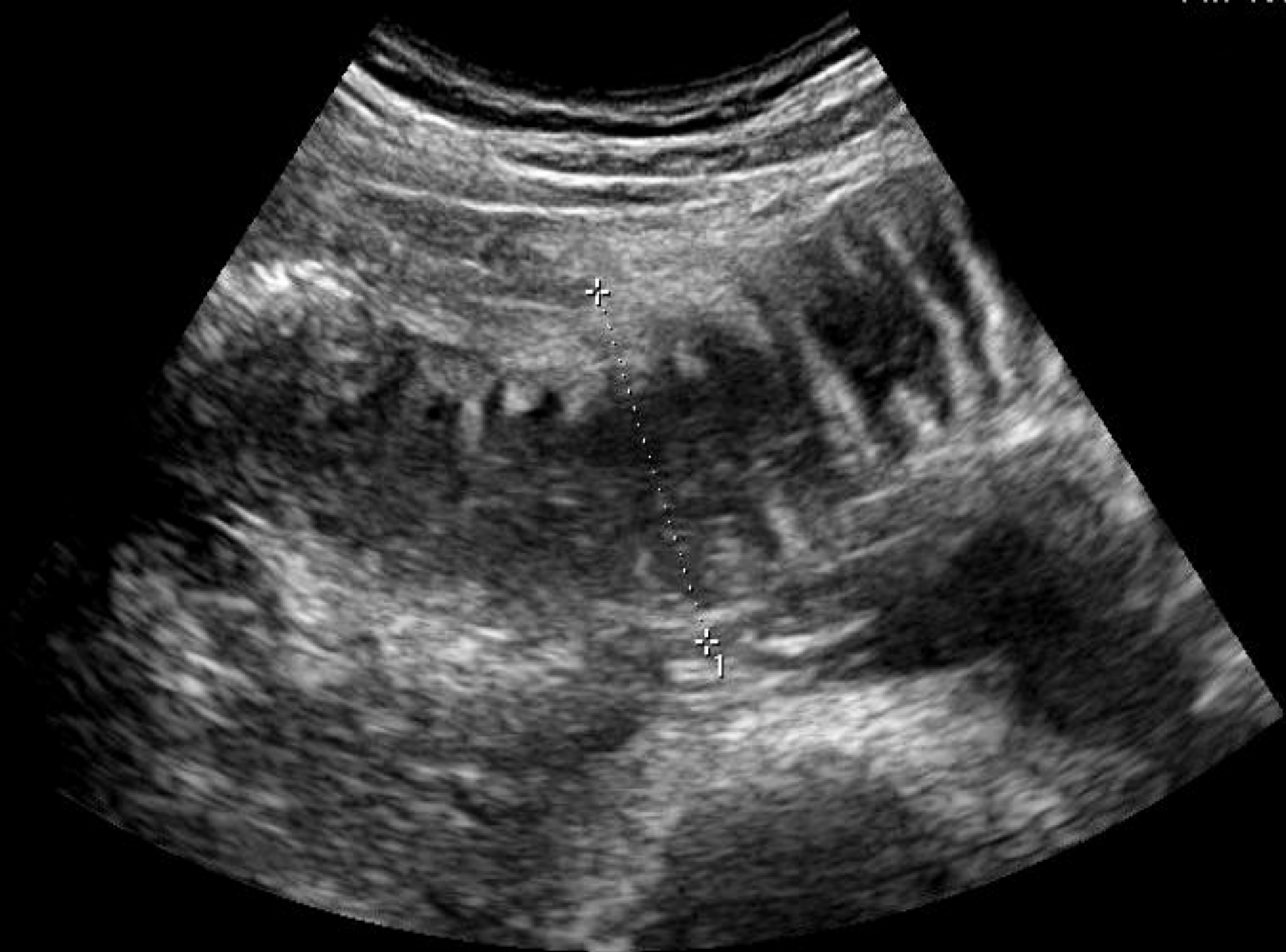

70.4 %









5



6

4

2

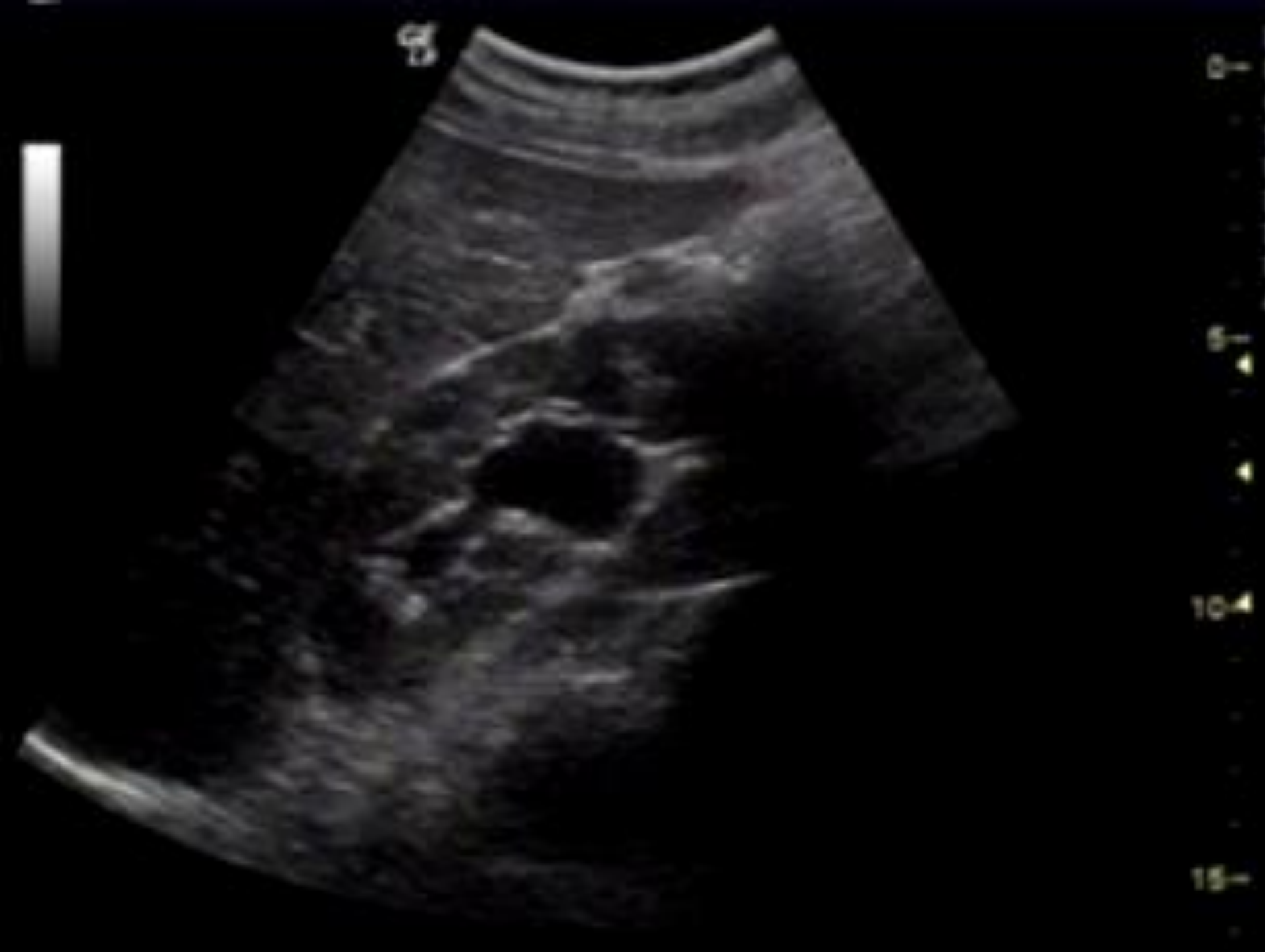0



M



1/223



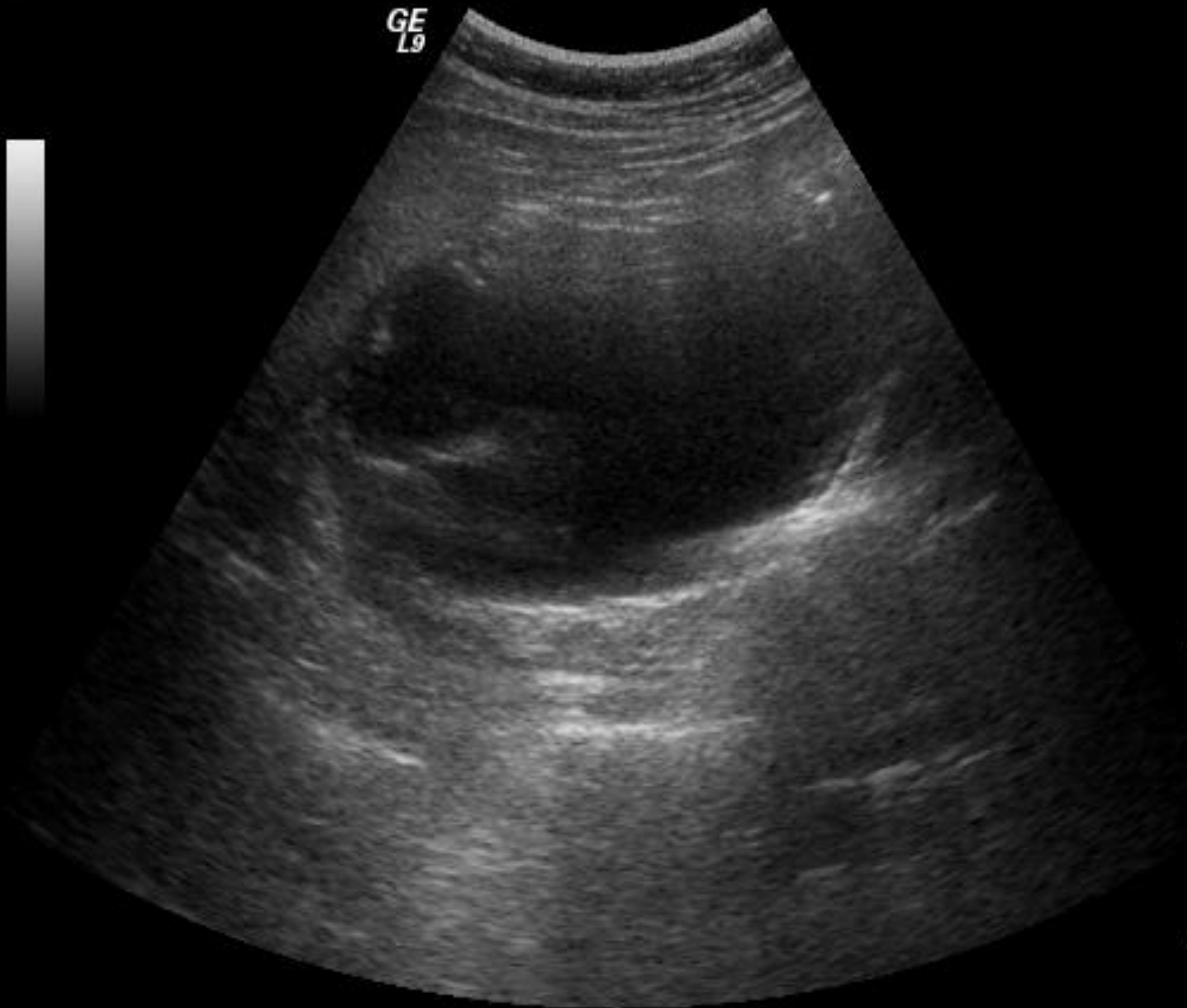
GE  
L9



GE  
L9



B  
0- Frq 8.0 MHz  
Gn 29  
- S/A 0/2  
- Map H/0  
D 16.0 cm  
- DR 78  
FR 10 Hz  
AO 100 %

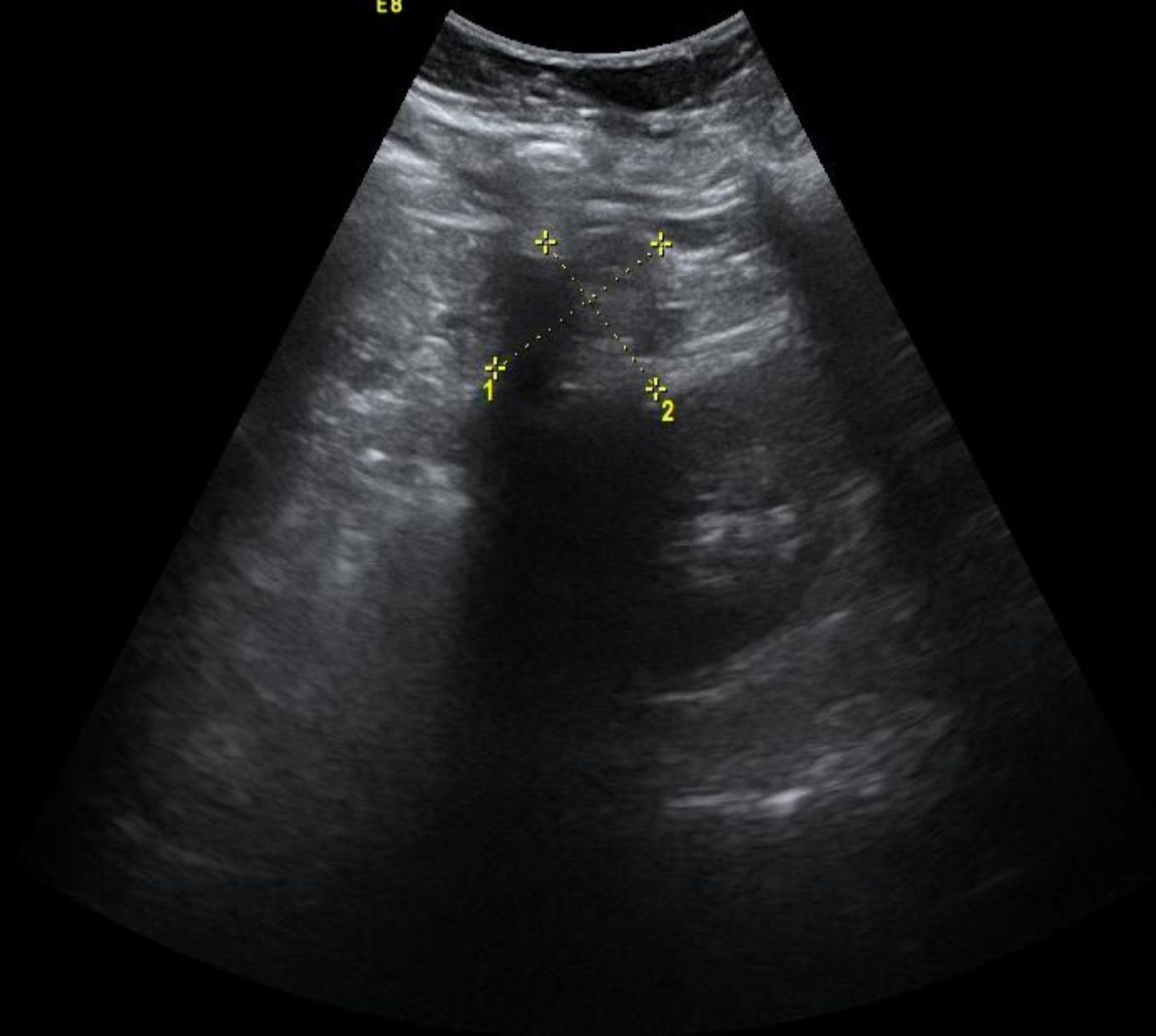


5-  
10-  
15-



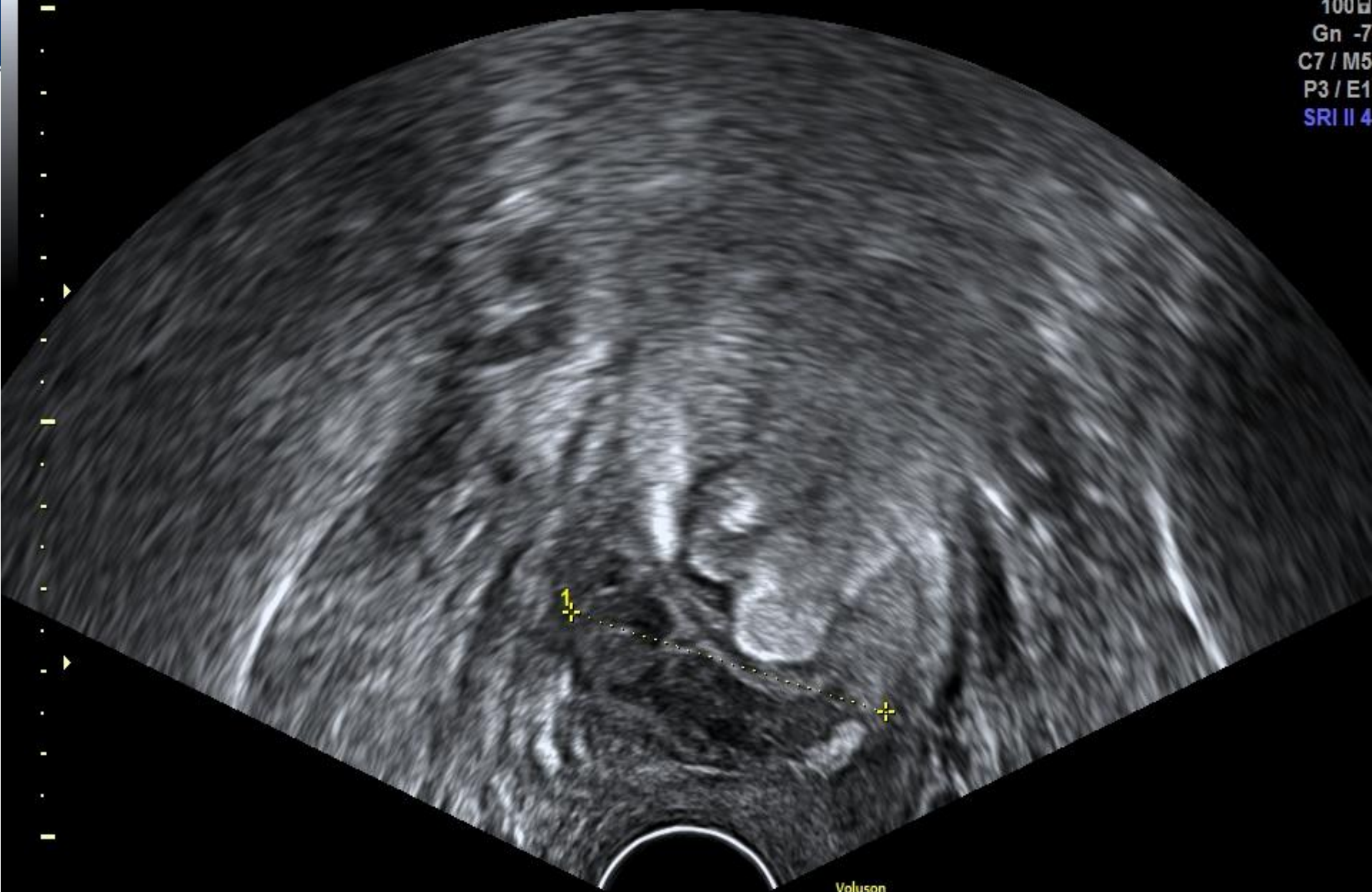
Voluson  
E8

Har-low  
100g  
Gn 0  
C8 / M4  
P3 / E3  
SRI II 3



1 D 3.45cm  
2 D 2.97cm

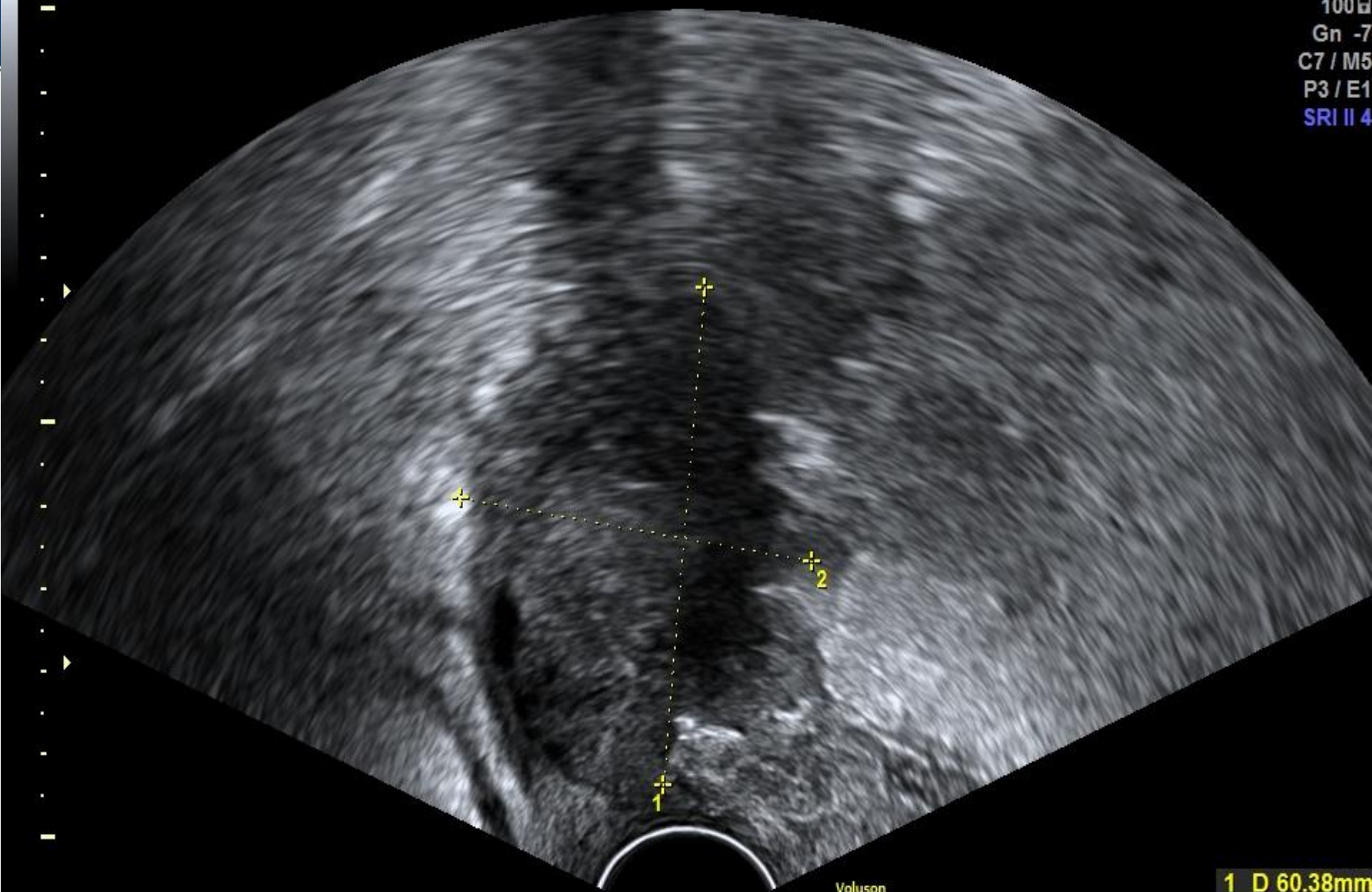
Penetration  
8.10 - 2.10  
100µ  
Gn -7  
C7 / M5  
P3 / E1  
SRI II 4



Voluson  
E8

1 D 43.05mm

Penetration  
8.10 - 2.10  
100dB  
Gn -7  
C7 / M5  
P3 / E1  
SRI II 4

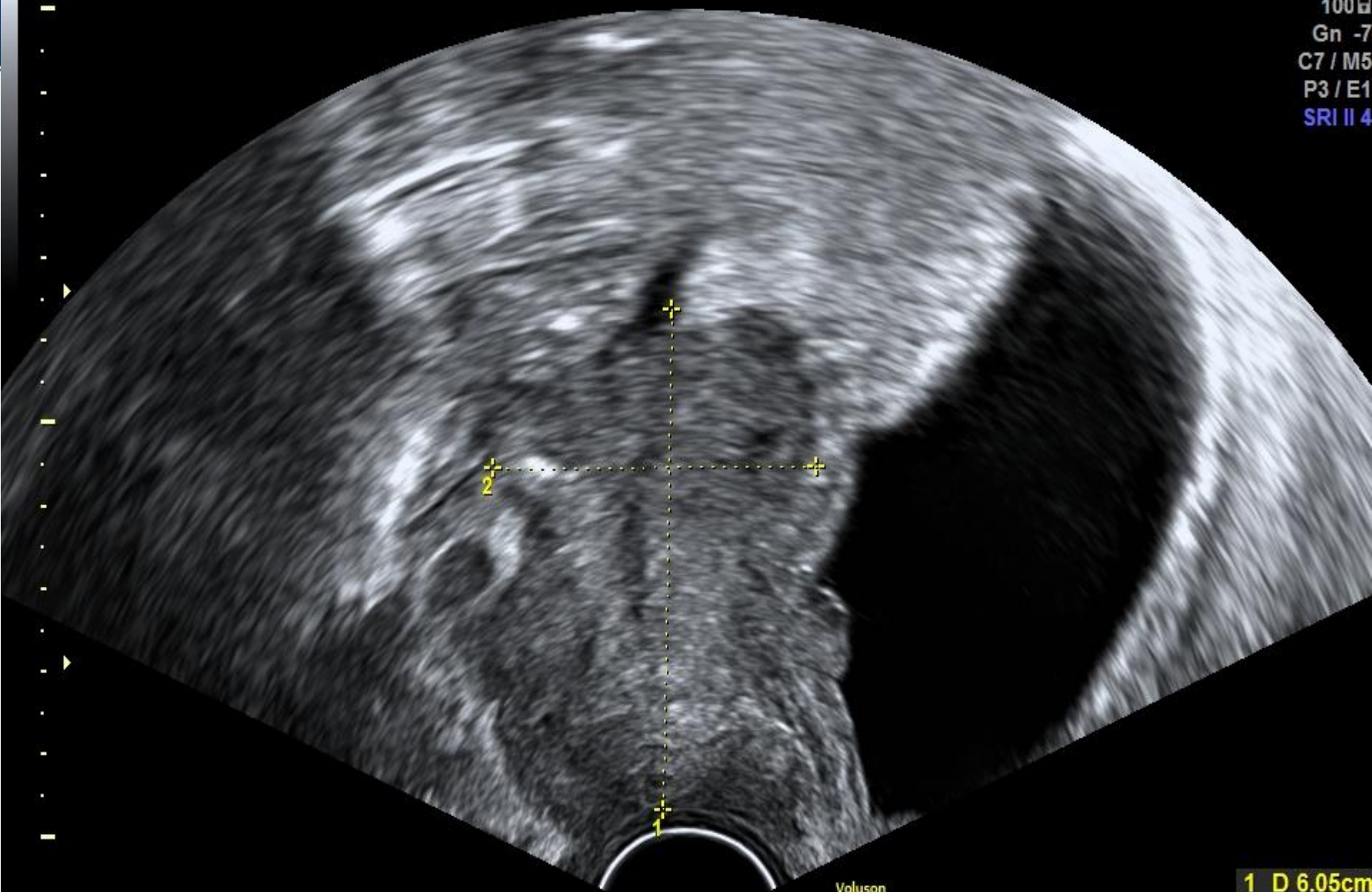


Voluson  
E8

1 D 60.38mm  
2 D 46.86mm



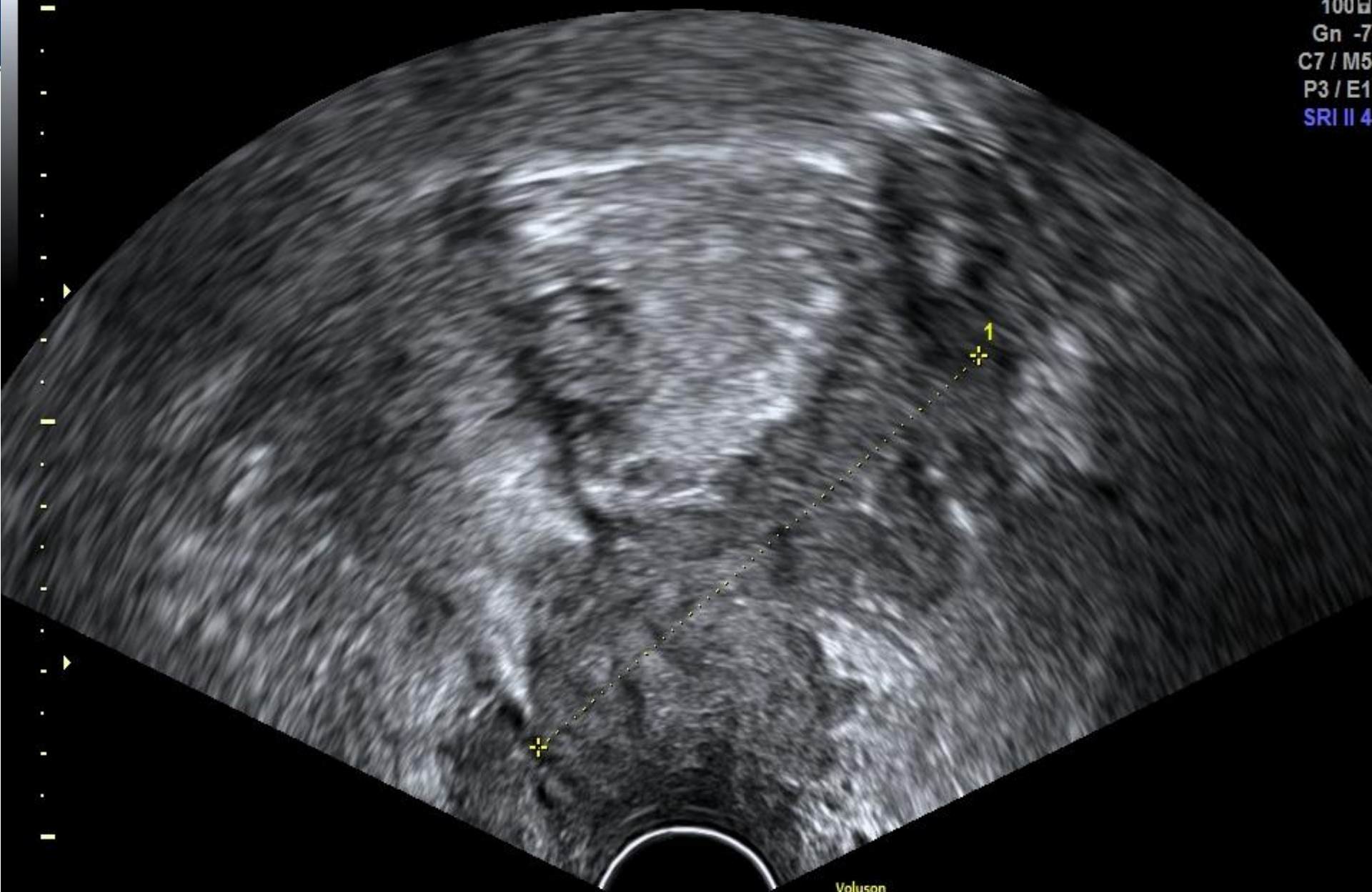
Penetration  
8.10 - 2.10  
100 $\mu$   
Gn -7  
C7 / M5  
P3 / E1  
SRI II 4



Voluson  
E8

1 D 6.05cm  
2 D 4.25cm

Penetration  
8.10 - 2.10  
100µ  
Gn -7  
C7 / M5  
P3 / E1  
SRI II 4



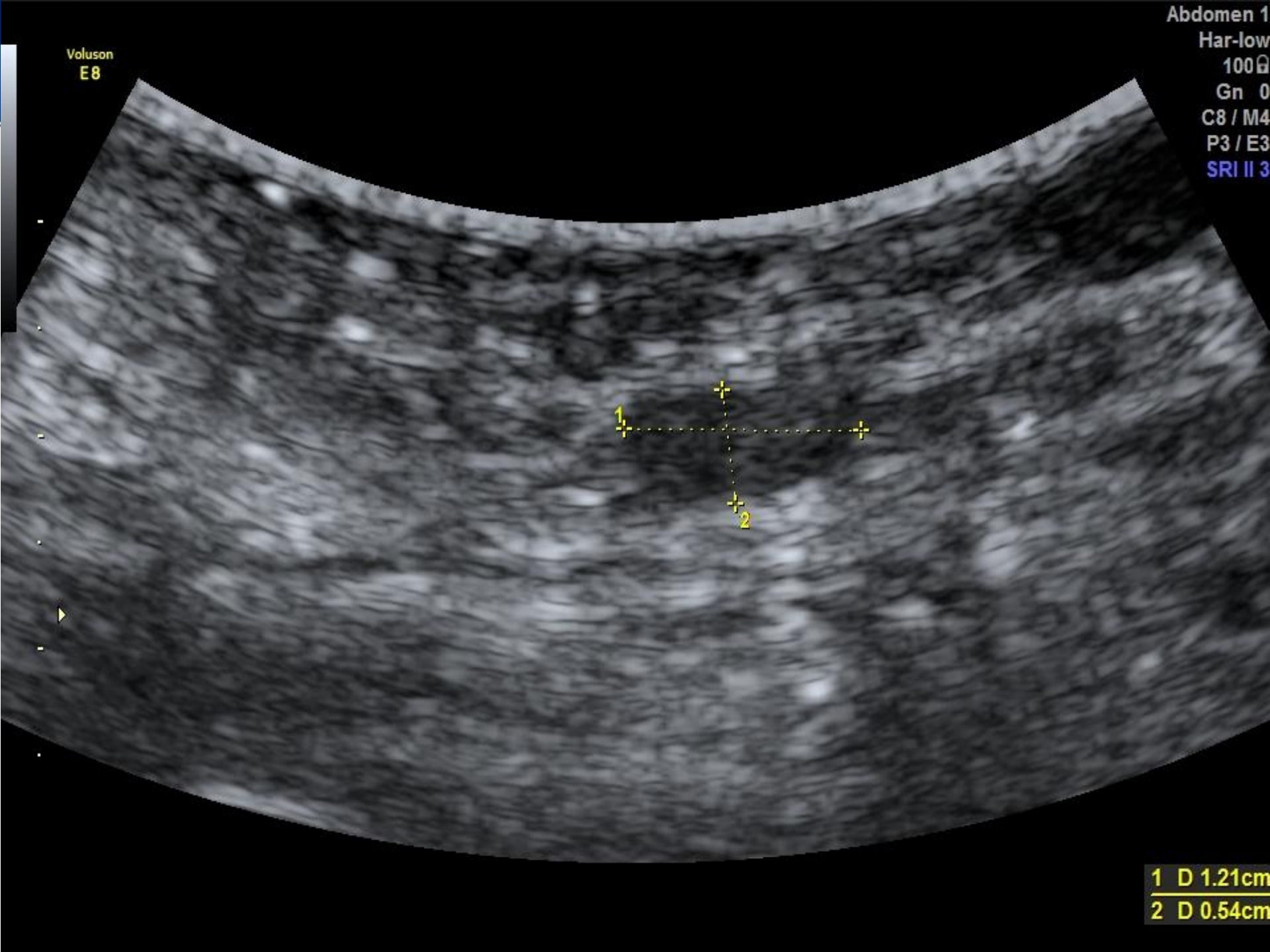
Voluson  
E8

1 D 7.48cm



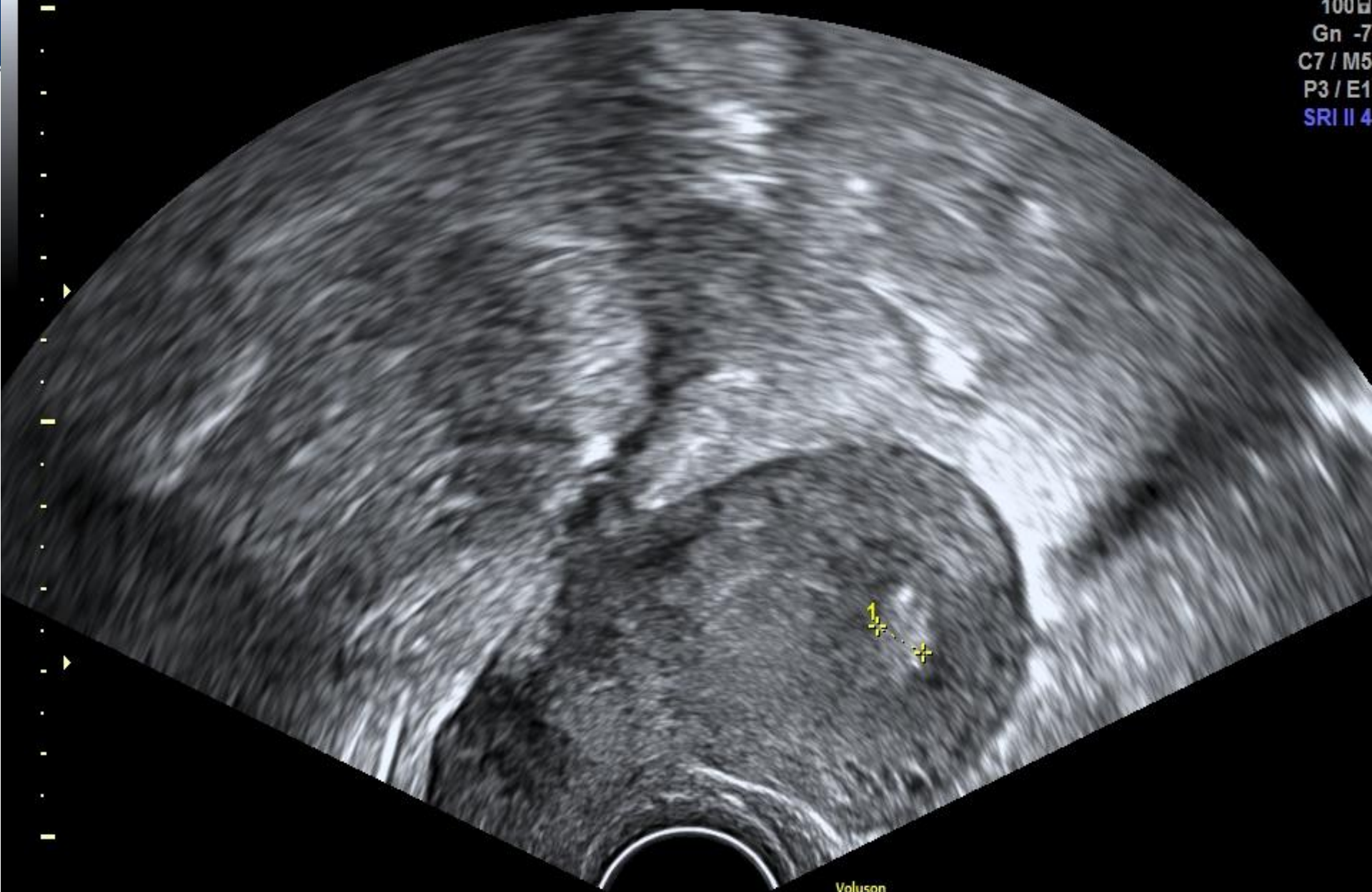Voluson  
E8

Abdomen 1  
Har-low  
100 $\mu$   
Gn 0  
C8 / M4  
P3 / E3  
SRI II 3



1 D 1.21cm  
2 D 0.54cm

Penetration  
8.10 - 2.10  
100µ  
Gn -7  
C7 / M5  
P3 / E1  
SRI II 4

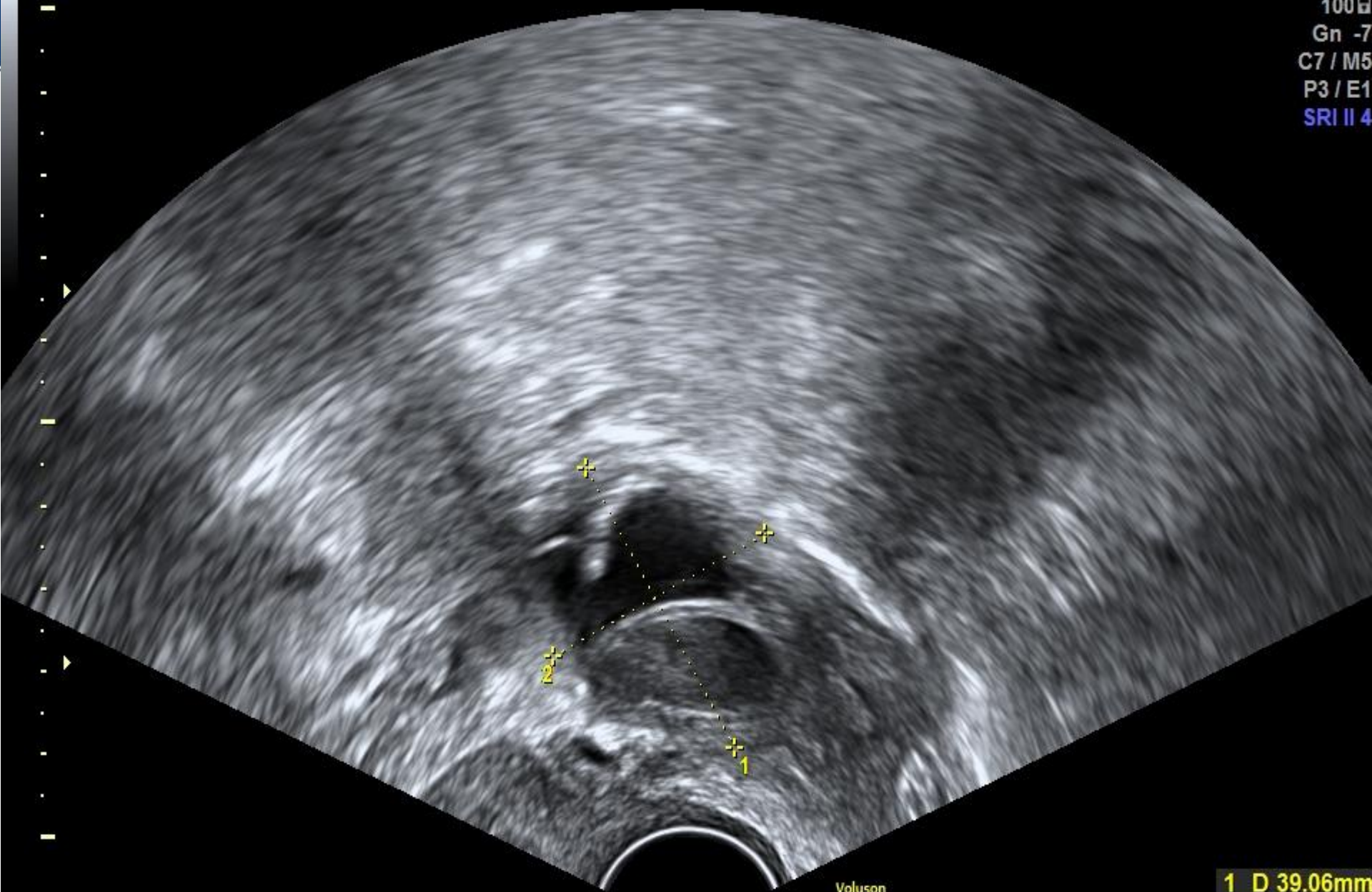


Voluson  
E8

1 D 6.81mm



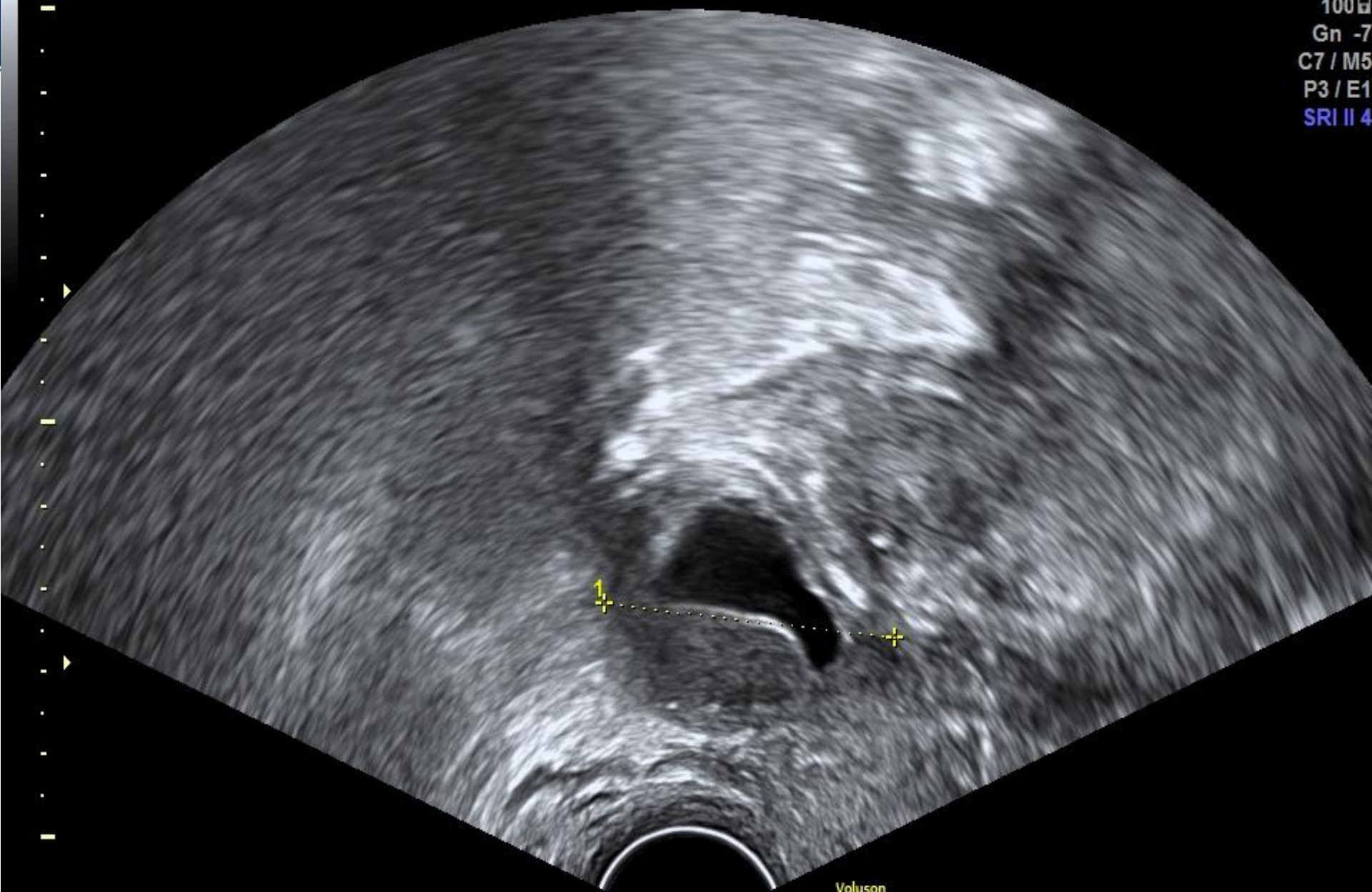
Penetration  
8.10 - 2.10  
100µ  
Gn -7  
C7 / M5  
P3 / E1  
SRI II 4



Voluson  
E8

1 D 39.06mm  
2 D 31.52mm

Penetration  
8.10 - 2.10  
100µ  
Gn -7  
C7 / M5  
P3 / E1  
SRI II 4

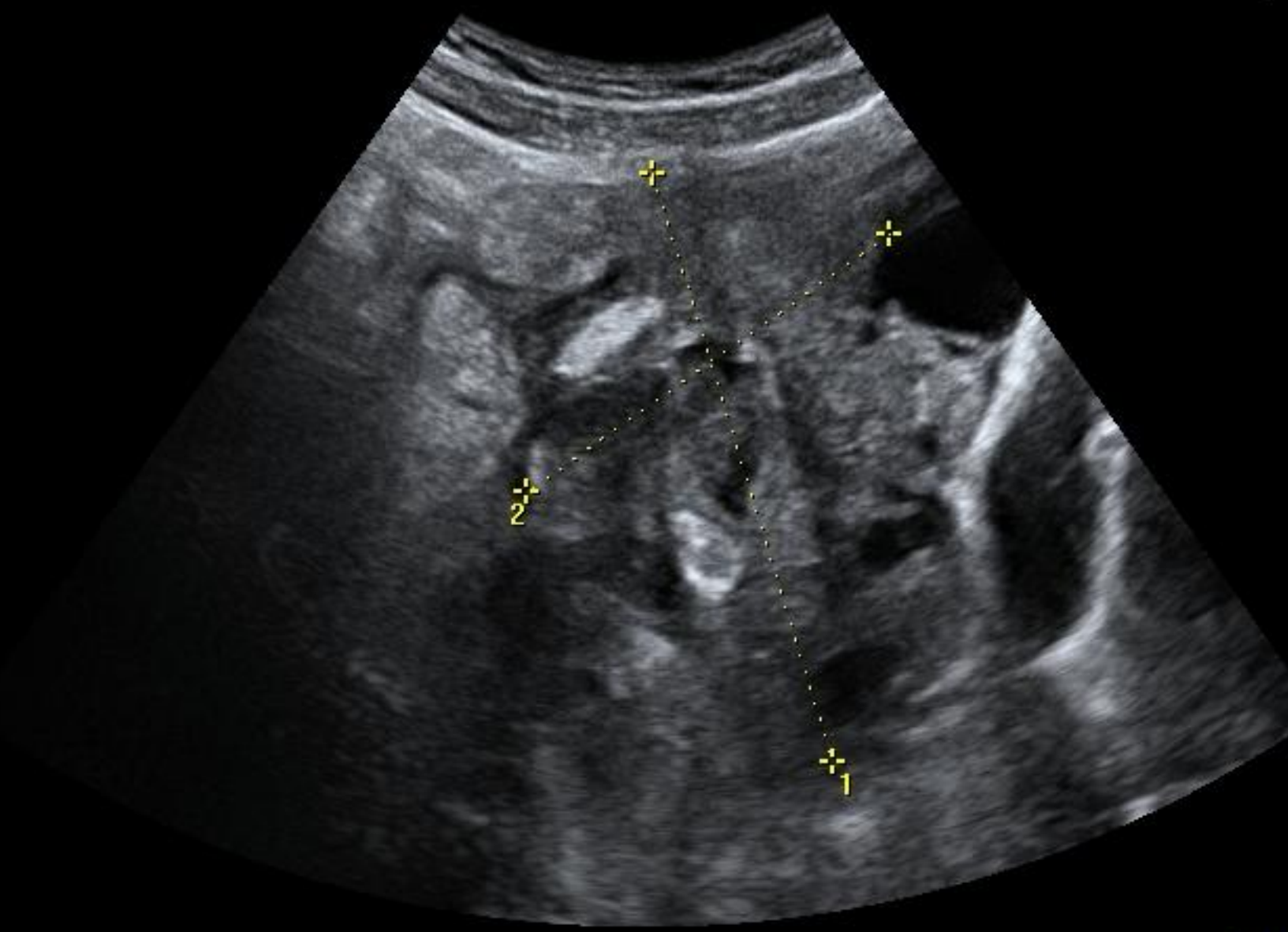


Voluson  
E8

1 D 38.37mm

2+3 T  
Har-  
Pwr 9  
Gn  
C7 /  
P3  
SRI

GE



1 D 8.37  
2 D 6.05



GE

2+3 Trim.  
Har-low  
Pwr 97 %  
Gn 5  
C7 / M7  
P3 / E2  
SRI II 3



1 D 5.84cm





1. LÉKAŘSKÁ FAKULTA  
UNIVERZITY KARLOVY V PRAZE



# Ultrazvuk a pooperační komplikace

Michal Zikán

*Onkogynekologické centrum  
1. LF UK a VFN  
Praha*